

Percutaneous Endoscopic Retrieval of Gizzard Foreign Body in a Goose Using an Operative Telescope

Pedro Paulo Maia Teixeira^{1,2}, Felipe Farias Pereira da Câmara Barros¹, Luisa Pucci Bueno Borges¹, Aline Eyko Kawanami³, Marco Augusto Machado Silva⁴, Karin Werther³,  Ricardo Russo Vicente³

ABSTRACT

Background: Foreign bodies are most commonly diagnosed in stomach (proventriculus and gizzard) of galliformes birds and waterfowl. Endoscopy is routinely used to assess birds' respiratory, gastrointestinal and urogenital tracts. Endosurgery is also used for sex determination and intra-coelomic organ biopsy. Benefits of endoscopic approaches are widely reported in birds. Conventional surgical approaches are far more invasive and risky for those patients. Thus, the purpose of this study was to describe a successful case of gizzard foreign body removal in a greylag goose (*Anser anser*), using a rigid endoscopic approach through a minimally invasive percutaneous access.

Case: A 2-year-old female greylag goose, weighting 3,116 g, was referred to a Veterinary Teaching Hospital presenting apathy and anorexia for at least 24 h. The results on hematologic assessment were within normal range for the species. Radiographic examination indicated presence of radiopaque content, resembling gizzard sediment. Thus, the patient underwent to endoscopy for examination and aspiration of the content. The goose was fasted for 6 h. Anesthesia was induced by face mask and maintained by endotracheal tube, using isoflurane vaporized in 100% oxygen. The patient was positioned in the lateral recumbence. The patient's neck was longer than the working length of the rigid endoscope. Thus, the telescope was inserted into the esophagus following a small distal esophagotomy, carried out on the caudal third of the neck. A 0° 10-mm operative rigid telescope, with a 6-mm working channel, and a 5-mm diameter and 42-cm in length laparoscopic Babcock forceps were used. The endoscope was inserted through the esophagotomy up to the ventricle level. Sand sediments and stones were viewed. The stones were grasped and retrieved, and the sediments were rinsed with normal saline solution and aspirated with a suction cannula through the working channel of the telescope. Inspection following sediment and foreign body retrieval revealed moderate inflammation of the gizzard mucosa. Total procedure time was 24 min. The patient recovered uneventfully and was discharged following 72 h.

Discussion: Rigid endoscopy provided accurate visualization of the thoracic esophagus, proventriculus and gizzard. In general, endosurgery is usually employed for sex determination in birds. It is also useful to access digestive tract using rigid endoscopy, in order to remove foreign body. Such minimally approach reduces postoperative morbidity, which is usually seen following conventional surgical approaches. This technique has been used for removal of foreign body in the digestive tract of several species. Foreign bodies found within crop should require ingluviotomy. However, could be easily removed by endoscopy. If the foreign body is within the proventriculus or gizzard, rigid endoscopy may be useful, as celiotomy could cause morbidity. The small esophagotomy access at the base of the neck was essential for the procedure. In short-necked birds, a 30° Trendelenburg positioning provides more caudal access to the digestive tract. In this case, such positioning was unnecessary. In conclusion, the use of an operative telescope provided accurate retrieval of foreign bodies and drainage of sediments within the digestive tract. Moreover, it can be used as a minimally invasive approach to foreign bodies in the esophagus, crop or stomach (esophagus and gizzard) of geese.

Keywords: Anatidae, *Anser anser*, digestive tract, operative telescope.

Received:  2016

Accepted:  mber 2016

Published:  ary 2017

¹Veterinary Hospital, University of Franca, Veterinary Science Graduate Program, Franca, SP, Brazil. ²Veterinary Institute, Medicine Veterinary College, Pará Federal University (UFPA), Campus II, Castanhal, PA, Brazil. ³Preventive Veterinary Medicine and Animal Reproduction Department, Agricultural Sciences and Veterinary Faculty, UNESP-University Paulista State "Júlio de Mesquita Filho", Jaboticabal, SP. ⁴College of Agronomy and Veterinary Medicine, University of Passo Fundo (FAMV/UPF), Passo Fundo, RS, Brazil. CORRESPONDENCE: P.P.M. Teixeira [p_paulomt@yahoo.com.br - Tel.: +55 (91) 981794736]. Veterinary Institute, Pará Federal University (UFPA), Campus II, Rodovia BR 316, Km 61. CEP 68740-970 Castanhal, PA, Brazil.

INTRODUCTION

Foreign bodies are most commonly diagnosed in proventriculus and gizzard of galliformes birds and waterfowl, but have also been reported in parrots and other species [6]. Endosurgery is routinely used to assess respiratory, gastrointestinal and urogenital tracts of birds. It is also used for sex determination and for taking liver and kidney biopsy [1,7,8]. The advantages of endoscopic approaches over conventional surgical access were widely reported [4,9]. Birds with long neck such as geese usually require special telescopes, as 30-cm standard laparoscopes are unable to reach distal esophagus and stomach. However, those special rigid endoscopes are usually expensive if available. Standard gastrointestinal flexible endoscopes could fill this gap, although they are also expensive and require much more experience from the endoscopist.

Thus, the purpose of this study was to report a successful case of gizzard foreign body retrieval in a greylag goose (*Anseranser*), using a rigid endoscope inserted through a minimally invasive esophagotomy access.

CASE

A 2-year-old female greylag goose (*Anseranser*), weighting 3,116 g, was referred to a Veterinary Teaching Hospital, presenting apathy and anorexia for at least 24 h. The results on hematological exam were within normal range for the species. Radiographic examination indicated the presence of radiopaque content in the gizzard, resembling sand sediment and small stones. The patient was submitted to endoscopic approach in order to confirm and retrieve foreign bodies and to drain the sediment.

The goose undergone a 6-h fasting. General anesthesia was induced using isoflurane¹ delivered by face mask. Anesthesia was maintained using isoflurane vaporized in 100% O₂, following endotracheal intubation. The animal was placed in left lateral recumbency. A 0°, 10 mm, 27 cm of working length operative telescope, with a 6-mm working channel (Nefroscope)², was available. However, the goose's neck was longer than the working length of the endoscope. Thus, a minimally invasive distal median esophagotomy was performed at the caudal final third of the neck (Figure 1). The telescope was inserted through the esophagotomy access, up to the gizzard level and sand sediment and small stones were seen (Figure 2). A 5-mm, 42 cm in length laparoscopic Babcock forceps² was used to

grasp and retrieve stones. Sand sediment was rinsed with normal saline solution and aspirated using a suction cannula inserted through the working channel of the telescope. Following complete retrieval, inspection revealed moderate inflammation of the gizzard mucosa. Esophagotomy site was closed in one-layer, using simple interrupted pattern with placement of the knots in the esophageal lumen, and muscles were reduced, both using monofilament absorbable suture. Skin was routinely closed using monofilament nylon suture. Total procedure time was 24 min.

The patient recovered uneventfully. Early post-operative prescription included parenteral tramadol hydrochloride (TramadolTM)¹ [4 mg.kg⁻¹, IM, BID] and meloxicam (MeloxicamTM)³ [0.4 mg.kg⁻¹, IM, BID] for 3 days, as well as enrofloxacin (FlotrilTM)⁴ [10 mg.kg⁻¹, VO, BID] for 7 days. There were no complications and the goose was discharged following 72 h of surgery.

DISCUSSION

This case report reveals an innovative approach to upper gastrointestinal endoscopic assess using rigid telescopes. To the authors' knowledge, there was no previous reports on percutaneous esophageal access to the caudal esophagus and stomach of long-necked exotic birds. Standard telescopes employed for laparoscopy and thoracoscopy often provide 27-33 cm of working length. This length may not be enough to reach the caudal esophagus of geese if transoral endoscopy is desired. It is reasonable that standard 110-cm in length standard gastrointestinal flexible scopes could fill this gap. Nevertheless, they are expensive and require much more experience from the endoscopist. Moreover, the narrow working channel of a standard gastroscope could easily be obstructed or damaged during aspiration of sand sediment or mud. In this study, the 6-mm working channel of the telescope enabled complete suction of all sediment and retrieval of larger stones. This issue makes this telescope a versatile instrument.

In this case report, the cranial aspect of the esophagus was not inspected, as preoperative imaging revealed no content cranially. Rigid endoscopy provided optimal visualization of the thoracic esophagus, proventriculus and gizzard. In general, endosurgery is widely used for sex determination in exotic birds. Rigid endoscopy has also been used to assess digestive tract for foreign body. Such approach decreases postoperative morbidity in comparison to conventional surgical approaches [3,5,9].

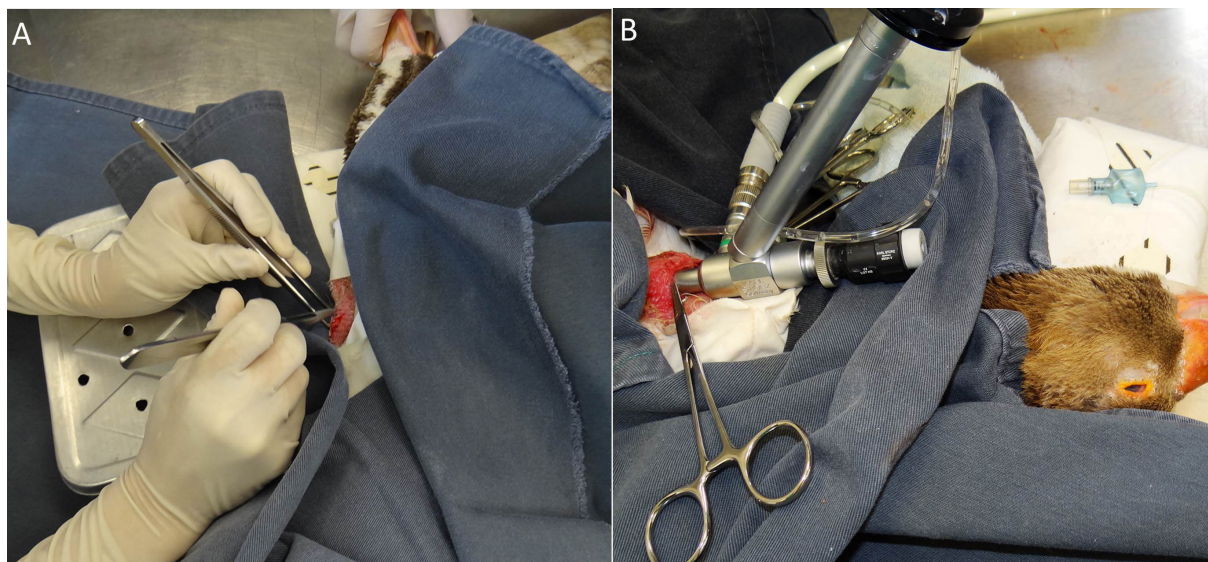


Figure 1. Procedimento cirúrgico em um ganso com sedimento no trato digestório. A- Local da esofagotomia na região ventral. B- Posicionamento da ótica videocirúrgica.

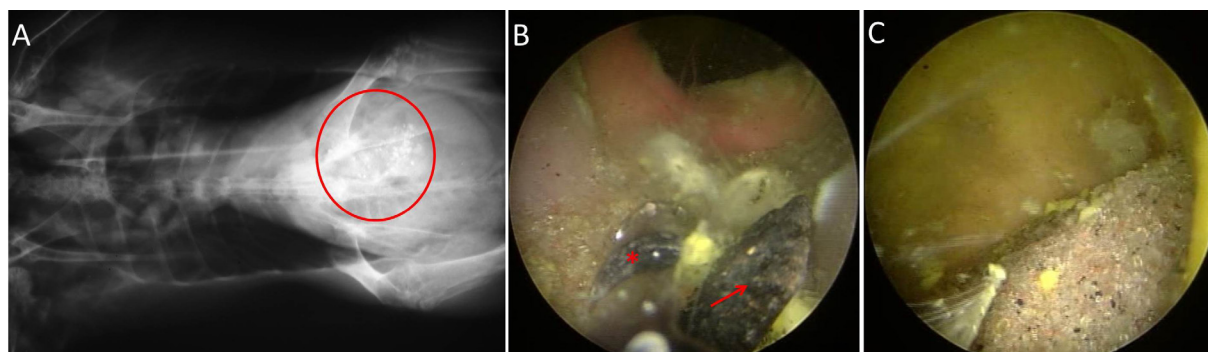


Figure 2. Imagem do sedimento no trato digestório de um ganso. A- Observa-se ponto radiopacos (círculo vermelho). B- e C- Visão endoscópica: observa-se um corpo estranho de tamanho maior (a) apreendido pela pinça videocirúrgica (asterisco). C- Visualização de grande quantidade de sedimento no proventrículo.

Rigid endoscopy has been used for removal of foreign body in the digestive tract in several species. Foreign bodies located in crop can be easily retrieved by endoscopy. Otherwise, ingluviotomy approach should be required. Proventriculus or gizzard foreign bodies are conventionally approached by celiotomy, usually resulting in postoperative morbidity. Thus, the use of rigid endoscopy provides better prognosis [2].

The minimally invasive esophagotomy access at the base of the neck was crucial to the success of the procedure. In short-necked birds, 30° Trendelenburg positioning provides access to the most caudal aspect of the esophagus, proventriculus and gizzard. In the current study, head-down tilt positioning was unnecessary [4,5,9].

In conclusion, the operative telescope provides optimal approach for gizzard foreign body retrieval

in geese, through a minimally invasive access to the caudal esophagus. This technique should be considered for removal of geese esophagus, crop or stomach (esophagus and gizzard) foreign bodies. A minimally invasive surgical access may be needed depending on the affected area.

MANUFACTURERS

¹Laboratório Cristália. São Paulo, SP, Brazil.

²H. Strattner & Cia. Ltda. Rio de Janeiro, RJ, Brazil.

³Eurofarma Laboratórios S.A. Ribeirão Preto, SP, Brazil.

⁴Schering-Plough. São Paulo, SP, Brazil.

Acknowledgements. The authors would like to thank the staff from the Veterinary Teaching Hospital (FCAV/UNESP) for cooperation in meeting the case.

Declaration of interest. The authors report no conflicts of interest. The authors alone are responsible for the content and writing of the paper.

REFERENCES

- 1 **Bottcher M. 1982.** Experiences with diagnostic endoscopy in birds. *Tierärztliche Praxis*. 10(2): 183-188.
- 2 **Chavez W. & Echols M.S. 2007.** Bandaging, endoscopy, and surgery in the emergency avian patient. *Veterinary Clinics of North America: Exotic Animal Practice*. 10(2): 419-436.
- 3 **Cornelissen H. & Ritchie B.W. 1994.** Ramphastidae. In: Ritchie B.W., Harrison G.J. & Harrison L.R. (Eds). *Avian medicine: principles and application*. Lake Worth: Wingers Publishing Inc., pp.1276-1283.
- 4 **Divers S.J. 2010.** Avian diagnostic endoscopy. *Veterinary Clinics of Exotic Animal*. 13(2): 187-202.
- 5 **Gancz A.Y. & Taylor W.M. 2006.** Applications of endoscopy for avian medicine. *Israel Journal of Veterinary Medicine*. 61(1): 20-25.
- 6 **Gelis S. 2008.** Evaluating and treating the gastrointestinal system. In: Harrison G.J. & Lightfoot T.L. (Eds). *Clinical Avian Medicine*. Source: <<http://ivis.org>>. [Accessed online February 2016].
- 7 **Ingram K.A. 1978.** Laparotomy technique for sex determination of psittacine birds. *Journal of the American Veterinary Medical Association*. 173(9): 1244-1246.
- 8 **Jones D.M., Samour J.H., Knight J.A. & Finch J.M. 1984.** Sex determination of monomorphic birds by fibreoptic endoscopy. *Veterinary Record*. 115(23): 596-598.
- 9 **Teixeira P.P.M., Coutinho L.N., Kawanami A.E., Silva A.S.L., Teles P.H.F., Brito M.S.B., Barros F.F.P.C., Silva M.A.M., Werther K. & Vicente W.R.R. 2013.** Use of a Standard Operative Laparoscope for Ventriculus Foreign Body Removal in a Toco Toucan (*Ramphastostoco*). *Acta Scientiae Veterinariae*. 41(Suppl 1): 1-3.

